

Clinical And Demographic Profile of Vernal Keratoconjunctivitis At A Tertiary Eye Care Center in Andhra Pradesh

Dr. I.S.V.S. Prasada Rao¹, Dr.Pidakala Shyam Sundar²,Dr. Sunil Kumar Naik³,
Dr. Sreevani.S³.

¹Associate professor, Department of Ophthalmology, Andhra Medical College, Dr. NTR University of Health Sciences, India

²Assistant Professor, Department of Ophthalmology, Andhra Medical College, Dr. NTR University of Health Sciences, India

³Post Graduates, Department of Ophthalmology, Andhra Medical College, Dr. NTR University of Health Sciences, India

Abstract

Back ground : Vernal keratoconjunctivitis (VKC) is an allergic disease that typically affects young individuals with male preponderance.[1,2] Prevalence of VKC is seen in the regions with hot, humid climate, and higher load of airborne allergens. Patients with VKC experience significant morbidity, which affects the quality of life;[8] moreover, vision-threatening corneal complication in severe and chronic cases coupled with potential iatrogenic side effects makes VKC a concerning ocular surface disorder.

Material&methods:

Study design:Hospital based cross sectional descriptive study

Study setting &subjects: ophthalmology OPD,AMC,Vizag. 250 patients suggestive of VKC were identified

Study period: January 2015 to December 2015

Statistical analysis: percentages

Results&conclusion: . Perennial pattern in large number of patients, persistent disease beyond the age of 20 years with adult onset disease patients and higher propensity for corticosteroid-induced cataract and glaucoma are certain findings seen in our study that one should consider during management of these cases. The commonest signs were palpebral papillae (89%) Conjunctival /ciliary congestion (79%) and highest number 108(43.2%) of the patients in the month of May. The male (M) to female (F) ratio was 2.5:1.106 patients (42.4%) belonged to high socioeconomic group, while 144 patients (57.6%) belonged to low. We had 241 (96.4%) patients with visual acuity ranging betw

Keywords: Allergic Eye Disease, Papillae, Shield ulcer, Vernal Keratoconjunctivitis

I. Introduction

Vernal keratoconjunctivitis (VKC) is an allergic disease that typically affects young individuals with male preponderance. [1,2] Greater prevalence of VKC is seen in the regions with hot, humid climate, and higher load of airborne allergens. It is a common ocular surface disorder in the Mediterranean region, central Africa, India, and South America. [1- 7] Clinically, it is characterized by presence of papillary hypertrophy of the palpebral and/or the limbal conjunctiva, bulbar conjunctivalpigmentation, limbal thickening, Horner Trantas dots, and mucous discharge. Patients with VKC experience significant morbidity, which affects the quality of life; [8] moreover, vision- threatening corneal complication in severe and chronic cases coupled with potential iatrogenic side effects makes VKCa concerning ocular surface disorder.The clinical profile of this disease seems to have geographicalvariations.[2- 7] However, there are no major series explaining thedemographic and clinical pattern of VKC from this part the world; hence, we conducted a retrospective chart analysis to study the pattern of VKC in a tertiary eye care centre insouthern India.

II. Materials And Methods

The present study is carried out after obtaining Approval from the Institutional Review Board (ethics committee of the institution), and consent from study participants.

A prospective analysis of all patients of VKC who presented to our Tertiary Eye Care Institute in South India Andhrapradesh from January 2015 to December 2015was done. A total of 250 VKC patients were identified. The diagnosis of VKC was made on the basis of history and typical signs and symptoms. Active VKC was diagnosed based on the complaint of ocular itching in the presence of upper tarsal conjunctival papillae and/or limbal hypertrophy with bulbar conjunctival pigmentation.[1] The quiescent form was diagnosed on the basis of inactive upper tarsal conjunctival papillae and/or scarring and a previous history of ocular

itching. The following data was recorded - Age, gender, personal and family allergies, age of onset of the disease, presenting symptoms, duration of disease, and details of ophthalmic examination including visual acuity, slit lamp examination for clinical signs, intraocular pressure, fundus examination, details of treatment (medical and surgical), and complications. Depending upon the clinical indications, the findings noted on examination under anesthesia or ancillary tests such as corneal topography by orb scan performed were also included. The palpebral form included patients with characteristic signs of cobble stone papillae of >1 mm on the upper tarsal conjunctiva with no limbal infiltration, while the limbal form consisted of papillae of <1 mm on the upper tarsal conjunctiva with limbal infiltration, and mixed form had features of both palpebral and limbal types of VKC. The severity of the disease was retrospectively graded based on the clinical signs at initial presentation, as per the method described by Bonini *et al.*[9] Visual impairment was assessed by means of the World Health Organization criteria for visual disabilities as used by Tabbara *et al.*[5]

Inclusion Criteria

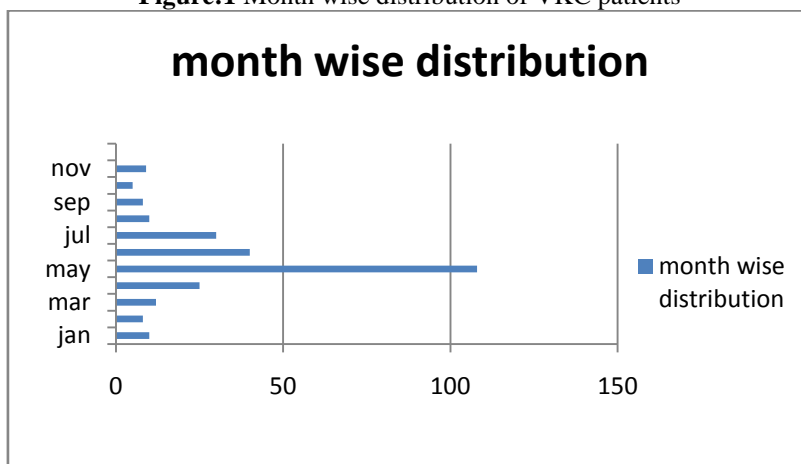
1. Patients suspicious with signs and symptoms of VKC.

Exclusion Criteria

- 1. Patients with other ocular diseases.
- 2. Patients with other ocular trauma.

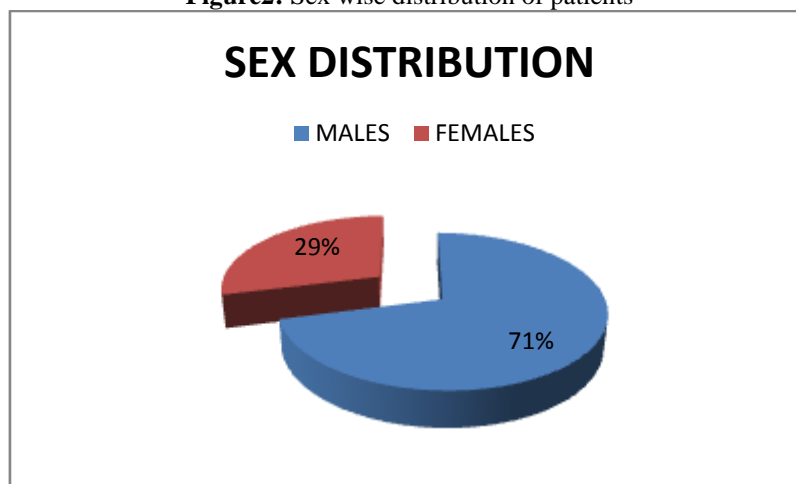
Results

Figure:1 Month wise distribution of VKC patients



Month-wise distribution showed highest number 108(43.2%) of the patients in the month of may

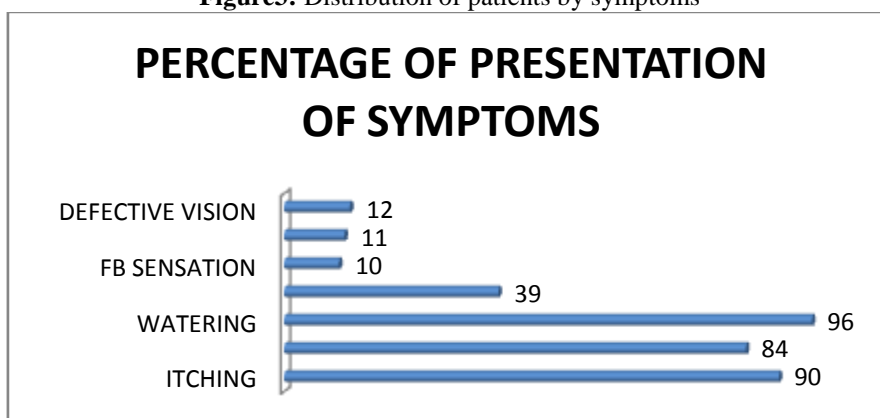
Figure2: Sex wise distribution of patients



The male (M) to female (F) ratio was 2.5:1. The disease was active at initial presentation in 205 individuals (82%). Patients who had their first episode at or after 20 years of age were categorized as adult onset VKC. thirty eight (15.2%) were aged ≥20 years at the time of presentation, of which 20(8%)(13 males, 7

females) patients had an adult onset of disease, while the rest had primarily a childhood disease that continued beyond 20 years o

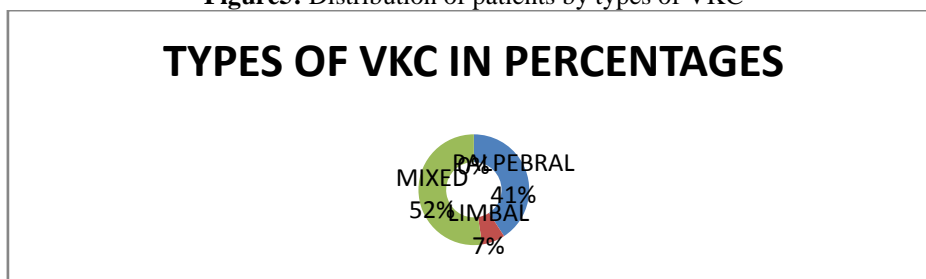
Figure3: Distribution of patients by symptoms



The commonest signs were palpebral papillae (89%) Conjunctival /ciliary congestion (79%) and limbal thickening (61%). Perilimbal conjunctival pigmentation was present in (24%) of patients. Chronic perennial form of VKC, lasting for more than 48 months was present in 118 patients (47.2%).

Isolated limbal form of VKC was present in 17 patients (6.8%), while isolated palpebral form was seen in 102 patients (40.8%). The majority (131; 52.4%) of patients had a mixed form of disease with involvement of both limbal and palpebral areas.

Figure5: Distribution of patients by types of VKC



The socio-economic status based distribution of these patients showed that 106 patients (42.4%) belonged to high socioeconomic group, while 144 patients (57.6%) belonged to low socioeconomic group. The criteria for low and high socioeconomic status were based on the nonpaying and paying categories of the patients, respectively.

Figure6: Distribution of patients by SES

Socioeconomic Status(Ses)	Percentage Of Patients
High Ses	42.2%
Low Ses	57.6%

The socio-economic status based distribution of these patients showed that 106 patients (42.4%) belonged to high socioeconomic group, while 144 patients (57.6%) belonged to low socioeconomic group. The criteria for low and high socioeconomic status were based on the nonpaying and paying categories of the patients, respectively. In the present series, 136 patients (54.4%) had either a positive family or personal history of atopy or allergic disorders, of which 67(47.90) had positive family history and 36(47.2) had a personal history of allergic diseases that included respiratory tract-related allergies in 17 (variably termed as “dust allergy,” rhinitis, bronchitis, and asthma by patients) and allergic dermatitis in 19 patients.

Table7: Distribution of patients by visual acuity

visual acuity	PERCENTAGE OF PATIENTS
6/6-6/18	96.4%
6/18-6/60	3.6%
<6/60	NIL

We had 241 (96.4%) patients with visual acuity ranging between 6/6-6/18 (normal, classification of visual impairment, WHO1977), 9 (3.6%) patients with visual acuity ranging 6/18-6/60 (low vision).

Corneal shield ulcers were seen in 23(9.2%)patient. similar pattern is seen in the study by virender etal where Corneal shield ulcers were present in 3% of patients; however, slightly greater incidence of corneal shield ulcers were reported by Bonini *et al.*,[12] (9.7%) and Leonardi *et al.*,[3] (15.3%) as compared to the present series.Peripheral corneal neovascularisation was seen in 12 (4.8%) patient. Similar but slightly higher percentage is seen in the study by virender etal, where isolated peripheral corneal neovascularisation was seen in 7.26% of patients. Peripheral corneal neovascularisation is a known finding in VKC and has been reported by other series, although the magnitude was not reported. Associated clinical manifestations like squamous blepharitis seen in 20(4%) patients. Bitots spots in 12 cases. All patients were treated with topical corticosteroids in the active stage of disease along with mast cell stabilizers or antihistaminic eye drops for long-term prophylactic use.

III. Discussion

Our study showed that VKC in the tropical Indian subcontinent is essentially similar to the pattern described in other tropical countries. The pattern here is predominantly mixed form of disease (53%) with significant number of patients having chronic perennial form (56%). Slightly higher propensity for VKC and its treatment-associated complications were seen. Persistent disease beyond 20 years of age was seen in increased number of patients (12%). To the best of our knowledge and Pub Med search results; this is the largest series from this part of the world. A total of 250 patients of VKC presented from Jan 2015 Jul 2016. Month-wise distribution showed highest number (43.2%) , in the month of May. Similar pattern can be noted in the study by virender sangwan etal showed highest number (71; 15%) of the patients in the month of May which is lower in value as compared to this series. The mean age at presentation was 8.33 years (Range3-27). Similar pattern with a mean age at presentation was 12 years by virender sangwan etal in theArticle *in* Indian Journal of Ophthalmology 61(9):486-489 · September 2013.

There are 178 (71%) males and 72 (29%) females in this series. The male (M) to female (F) ratio was 2.5:1. Supporting this pattern Leonardi and co-workers in their two separate observations including a multicentric study from Italy found M:F ratio between 3.3 and 3.5. Ukponmwan reported a female preponderance (M:F ratio of 1:1.3) from Nigeria; however, another report from that region suggested M:F ratio of 1.27. M:F ratio in this study is slightly higher than those reported from other parts of the world, but confirms the global pattern of male preponderance of VKC. Patients who had their first episode at or after 18 years of age were categorized as adult onset VKC. VKC is believed to be a disease of childhood and usually resolves at puberty. Interestingly, we found that in our series 38 patients (15.2%) were aged ≥ 18 years at the time of presentation, of which,females (15), males (23) ,20(8%)patients had an adult onset of disease, while 18 (7.2%)patients had primarily a childhood disease that continued beyond 20 years of age. Similar pattern was seen in the case series of virender etal with 12% above 20 years of age, of these 3.5% patients had an adult onset of disease and others had childhood disease which had persisted beyond the age of 20 years. Similar patterns are seen with a slight lower rate in Leonardi *et al.*, (4% of patients above the age of 20 years) and Shafiq *et al.*, (6% of patients with VKC above the age of 20 years)The common reported symptoms were itching(100%),watering (90%).and redness(84%) The commonest signs were palpebral papillae (89%), Conjunctival /ciliary congestion (79%) and limbal thickening (61%). Perilimbal conjunctival pigmentation was present in (24%) of patients. This pattern can be noted in the study by virender sangwan etal as common reported symptoms were itching (88%), redness (86%), and watering (65%).

The commonest signs were palpebral papillae (89%) and limbal thickening (61%). Perilimbal conjunctival pigmentation was present in 24 % of patients.VKC has seasonal exacerbations; however, chronic perennial form of VKC, lasting for more than 48 months was present in 118 patients (47.2%). has also been described as seen in 36% of patients in the study by virender etal which is slightly lower in value as compared to the present series. Isolated limbal form of VKC was present in 17 patients (6.8%), while isolated palpebral form was seen in 102 patients (40.8%). The majority (131; 52.4%) of patients had a mixed form of disease with involvement of both limbal and palpebral areas. Similar pattern of reports can be seen in the study by virender sangwan etal as Isolated limbal form of VKC was present in 59 patients (12.6%), while isolated palpebral form was seen in 73 patients (15.6%), which is lower than the present series. The majority (336; 72%) of patients had a mixed form of disease with involvement of both limbal and palpebral areas which is higher than the present series. The prevalence of subtypes of VKC is different in various parts of the world. The multi centric study by *Lambiase etal*from Italy reported predominance (53.8%) of limbal presentation, whereas Ukponmwan reported 82.6% cases with palpebral presentation in Nigeria.

The socio-economic status based distribution of these patients showed that 101 patients (40.4%) belonged to middle class, 86(34.4%) belonged to upper-middle class 28 (11.02%) belonged to lower middle class (according to modified BG Prasad socio economic classification2014).In the present series, 136 patients

(54.4%) had a positive personal history of atopy or allergic disorders, of which 67(47.90%) had positive sinusitis/rhinitis history, 36 (47.2%) had bronchial asthma and allergic dermatitis 19 (13.97%) & food allergy in 14(10.29%) 51 (20.4%) had a family history of allergic diseases that included 41(16%) (Asthma) and allergy in 10(4%) patient. We had 241 (96.4%) patients with visual acuity ranging between 6/6-6/18 (normal, classification of visual impairment, WHO1977), 9 (3.6%) patients with visual acuity ranging 6/18-6/60 (low vision). corneal shield ulcers were seen in 23(9.2%) patient. similar pattern is seen in the study by virender et al where Corneal shield ulcers were present in 3% of patients; however, slightly greater incidence of corneal shield ulcers were reported by Bonini *et al.*, [12] (9.7%) and Leonardi *et al.*, [3] (15.3%) as compared to the present series. Peripheral corneal neovascularization was seen in 12 (4.8%) patient. Similar but slightly higher percentage is seen in the study by virender et al, where isolated peripheral corneal neovascularisation was seen in 7.26% of patients. Peripheral corneal neovascularisation is a known finding in VKC and has been reported by other series, although the magnitude was not reported. Associated clinical manifestations like squamous blepharitis seen in 20(4%) patients. Bitots spots in 12 cases. All patients were treated with topical corticosteroids in the active stage of disease along with mast cell stabilizers or antihistaminic eye drops for long-term prophylactic use.

IV. Conclusion

This study has shown that VKC in India is essentially similar to the typical pattern of VKC seen in other tropical countries. Perennial pattern in large number of patients, persistent disease beyond the age of 20 years with adult onset disease patients and higher propensity for corticosteroid-induced cataract and glaucoma are certain findings seen in our study that one should consider during management of these cases.

References

- [1]. Leonardi A, Secchi AG. Vernal keratoconjunctivitis. *Int Ophthalmol Clin.* 2003;43:41–58.
- [2]. Bonini S, Coassin M, Aronni S, Lambiase A. Vernal keratoconjunctivitis. *Eye (Lond)* 2004;18:345–51.
- [3]. Leonardi A, Busca F, Motterle L, Cavarzeran F, Fregona IA, Plebani M, et al. Case series of 406 vernal keratoconjunctivitis patients: A demographic and epidemiological study. *Acta Ophthalmol Scand.* 2006;84:406–10.
- [4]. Lambiase A, Minchiotti S, Leonardi A, Secchi AG, Rolando M, Calabria G, et al. Prospective, multicenter demographic and epidemiological study on vernal keratoconjunctivitis: A glimpse of ocular surface in Italian population. *Ophthalmic Epidemiol.* 2009;16:38–41. 5. Tabarra KF. Ocular complications of vernal keratoconjunctivitis. *Can J Ophthalmol.* 1999;34:88–92.
- [5]. Ukponmwan CU. Vernal conjunctivitis in Nigerians: 109 consecutive cases. *Trop Doct.* 2003;33:242–5.
- [6]. Akinsola FB, Sonuga AT, Aribaba OT, Onakoya AO, Adefule-Ositelu AO. Vernal keratoconjunctivitis at Guinness Eye Centre, Luth (a five year study) *Nig Q J Hosp Med.* 2008;18:1–4.
- [7]. Sacchetti M, Baiardini I, Lambiase A, Aronni S, Fassio O, Gramiccioni C, et al. Development and testing of the quality of life in children with vernal keratoconjunctivitis questionnaire. *Am J Ophthalmol.* 2007;144:557–63.
- [8]. Bonini S, Sacchetti M, Mantelli F, Lambiase A. Clinical grading of vernal keratoconjunctivitis. *Curr Opin Allergy Clin Immunol.* 2007;7:436–41.
- [9]. Shafiq I, Shaikh ZA. Clinical presentation of vernal keratoconjunctivitis (VKC): A Hospital based study. *J Liaquat Uni Med Health Sci.* 2009;8:50–4.
- [10]. Tuft SJ, Cree IA, Woods M, Yorston D. Limbal vernal keratoconjunctivitis in the tropics. *Ophthalmology.* 1998;105:1489–93.
- [11]. Bonini S, Bonini S, Lambiase A, Marchi S, Pasqualetti P, Zuccaro O, et al. Vernal keratoconjunctivitis revisited: A case series of 195 patients with long-term followup. *Ophthalmology.* 2000;107:1157–63
- [12]. Rao SK, Padmanabhan P. Perilimbal conjunctival pigmentation in vernal keratoconjunctivitis: A new sign. *Cornea.* 2002;21:432.
- [13]. Rao SK, Meenakshi S, Srinivasan B, Baluswamy S. Perilimbal bulbar conjunctival pigmentation in vernal conjunctivitis: Prospective evaluation of a new clinical sign in an Indian population. *Cornea.* 2004;23:356–9.
- [14]. Luk FO, Wong VW, Rao SK, Lam DS. Perilimbal conjunctival pigmentation in Chinese patients with vernal keratoconjunctivitis. *Eye (Lond)* 2008;22:1011–4.
- [15]. Sangwan VS, Jain V, Vemuganti GK, Murthy SI. Vernal keratoconjunctivitis with limbal stem cell deficiency. *Cornea.* 2011;30:491–6.
- [16]. Sangwan VS, Murthy SI, Vemuganti GK, Bansal AK, Gangopadhyay N, Rao GN. Cultivated corneal epithelial transplantation for severe ocular surface disease in vernal keratoconjunctivitis. *Cornea* 2005;24:426–30.